

Physical Therapy

Journal of the American Physical Therapy Association



Pathomechanics of Structural Foot Deformities

David Tiberio

PHYS THER. 1988; 68:1840-1849.

The online version of this article, along with updated information and services, can be found online at: <http://ptjournal.apta.org/content/68/12/1840>

Collections

This article, along with others on similar topics, appears in the following collection(s):

[Injuries and Conditions: Ankle](#)

[Injuries and Conditions: Foot](#)

[Kinesiology/Biomechanics](#)

e-Letters

To submit an e-Letter on this article, click [here](#) or click on "Submit a response" in the right-hand menu under "Responses" in the online version of this article.

E-mail alerts

Sign up [here](#) to receive free e-mail alerts

Pathomechanics of Structural Foot Deformities

DAVID TIBERIO

This article presents the most common structural foot deformities encountered in clinical practice. The deformities are defined, and the expected compensations at the subtalar joint (STJ) are described. The theoretical consequences of the STJ compensations on proximal and distal tissues are presented. A biomechanical rationale for certain tissue disorders is described. The possible effects of abnormal STJ compensation on osseous development are briefly discussed.

Key Words: *Foot deformities; Gait; Kinesiology/biomechanics, lower extremity; Lower extremity, ankle and foot; Subtalar joint.*

From an anatomical perspective, the foot is a complex group of bones and muscles. The foot is a marvelous structure when viewed from the perspective of biomechanical function. The foot must perform diverse functions at specific times during the gait cycle. Other articles in this issue discuss in detail the anatomy and biomechanical function of the foot. From a practical standpoint, the foot must 1) adapt to the ground surface and simultaneously facilitate the body's shock-absorbing mechanism and 2) function as a rigid lever to propel the body across the ground.¹ The normal (structurally undeformed) foot is adequately prepared to perform these functions.

When structural deformities exist in the foot, the subtalar joint (STJ) is likely to compensate. Although the deformities usually exist in a single plane, the compensatory motion of the STJ occurs in all three cardinal planes. Compensatory motion of the STJ interferes with the foot's ability to accomplish its primary functions. This article analyzes the anticipated STJ compensations in response to specific foot deformities. The effect (often theoretical) of STJ compensation on both distal and proximal structures will be described. Alternative compensations for structural foot deformities will also be discussed.

THE NORMAL FOOT

To understand the pathomechanics of foot function, knowledge must be acquired regarding the various structural foot deformities that are commonly encountered in clinical practice. The criteria for a normal foot provide the basis for identification of structural foot deformities. Figure 1 depicts the structural alignment of a normal foot during weight-bearing. When the STJ is in a neutral position (neither pronated nor supinated), the major components of the normal foot are 1) both plantar condyles of the calcaneus are on the surface, 2) all of the metatarsal heads lie in one plane, and 3) the plane of the metatarsal heads is the same plane as the plantar condyles of the calcaneus.¹ In addition, the orientation of the distal third of the lower leg should be vertical to position the foot properly for the stance phase. The orientation of the bones in the normal foot provides the basis for a clinical

examination (see article by Giallonardo in this issue). A brief discussion of these evaluation procedures will facilitate the description of specific foot deformities.

Subtalar Joint Neutral

The measurement of the STJ neutral position is actually a measurement of the angle between a line that bisects the distal third of the lower leg and a line that bisects the calcaneus (Fig. 2).² The bisection of the calcaneus represents the position of the plantar condyles, because the calcaneus is almost perpendicular to the condyles. The plane of the condyles should be perpendicular to the distal third of the leg. The angle between the bisections, therefore, should be zero degrees in the normal foot but actually is 2 to 3 degrees of varus (inverted) in most subjects. The slight varus of the calcaneal bisection usually is not apparent, and the calcaneus appears to be directly in line with the lower leg.³

Metatarsal Heads

The clinician, while maintaining STJ neutral, must assess whether all of the metatarsal heads are in the same plane. The second, third, and fourth metatarsal heads are usually in the same plane unless there has been some trauma or longstanding structural deviation. Deformities, whether structural or functional, are usually found in the first or fifth metatarsal heads because each of these heads has a separate axis of motion (see article by Oatis in this issue). Assessing alignment of the first metatarsal head to the second⁴ and the fifth metatarsal head to the fourth, therefore, becomes clinically important (Fig. 3).

Forefoot-to-Rear Foot Relationship

Once established, the plane of the metatarsal heads must be compared with the plantar surface of the calcaneus (forefoot-to-rear foot relationship). Evaluation of this relationship must be made in each of the cardinal planes. For frontal plane assessment, the calcaneal bisection is commonly used to compare the heel with the forefoot. The calcaneal bisection is almost perpendicular to the plantar condyles and, by inference, should be perpendicular to the plane of the metatarsal heads. If the plane of the metatarsal heads is perpendicular to the bisection of the calcaneus, the forefoot-to-rear foot relationship is normal or "neutral" (Fig. 4).²

D. Tiberio, MS, PT, is Assistant Professor, Program in Physical Therapy, University of Connecticut, School of Allied Health Professions, PO Box U-101, 358 Mansfield Rd, Storrs, CT 06268 (USA), and Consultant, West Hartford Physical Therapy, 29 N Main St, West Hartford, CT, and Director, On-Site Biomechanical Education and Training, PO Box 34, Storrs, CT 06268.

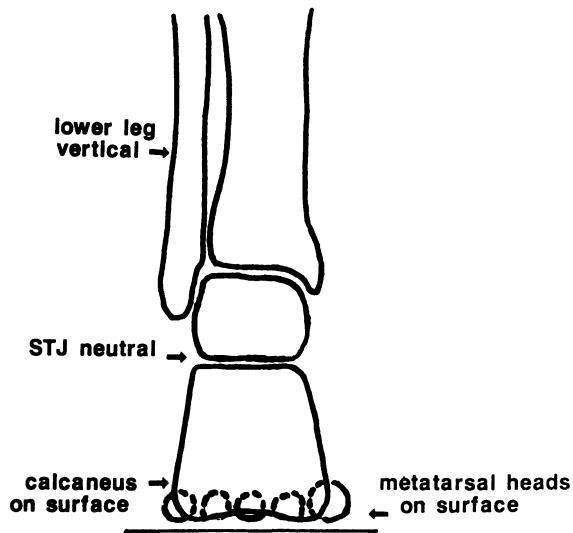


Fig. 1. Structural alignment of the normal foot during weight-bearing (STJ = subtalar joint). (Reprinted by permission of On-Site Biomechanical Education and Training, 1988.)

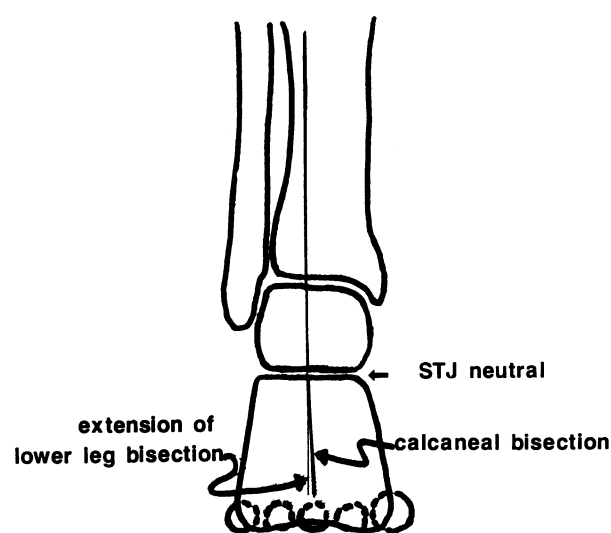


Fig. 2. Measurement of subtalar joint (STJ) neutral position indicating a slight varus angle in the normal foot. (Reprinted by permission of On-Site Biomechanical Education and Training, 1988.)

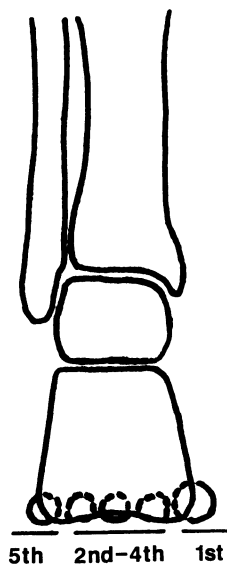


Fig. 3. Comparison of metatarsal head position. (Reprinted by permission of On-Site Biomechanical Education and Training, 1988.)

The relationship of the forefoot to the rear foot in the sagittal plane must also be assessed, because structural deformities may increase the amount of ankle dorsiflexion required for normal ambulation. An imaginary plane representing the ground surface is applied to the plantar surface of the calcaneus. The metatarsal heads should rest upon this plane (Fig. 5A). The transverse plane forefoot-to-rear foot relationship of a normal foot requires the forefoot to have the same longitudinal direction as the rear foot (rectus foot). This relationship, although difficult to measure, is readily observed in the STJ neutral position (Fig. 5B).

STRUCTURAL DEFORMITIES

The structural deformities described below are encountered frequently in clinical practice. The clinical incidence of these deformities probably does not reflect their incidence in the

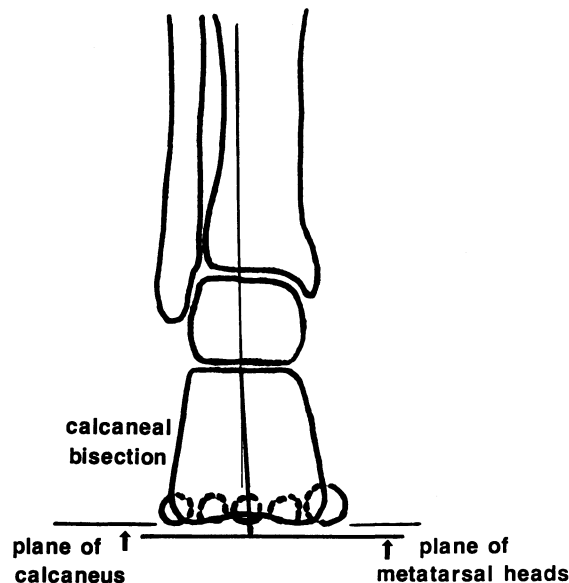


Fig. 4. Assessment of forefoot-to-rear foot relationship in the frontal plane. The plane of the metatarsal heads is perpendicular to the calcaneal bisection. (Reprinted by permission of On-Site Biomechanical Education and Training, 1988.)

general population, because certain deformities are more likely than others to produce dysfunction requiring treatment. Although much of what is known about the frequency of these deformities is anecdotal, a recent study on a select population of women supports clinical experience.⁵ The positions of the bone segments described in this section are with the STJ in a neutral position. Position changes resulting from ground-reaction forces will be discussed in the section on compensation.

The most common structural foot deformity is *rear-foot varus*. The most frequent and important component of a rear-foot varus is a calcaneal varus. A *calcaneal varus* (called a subtalar varus in the podiatric literature) is an inverted position of the calcaneus. It is caused by a failure of the calcaneus

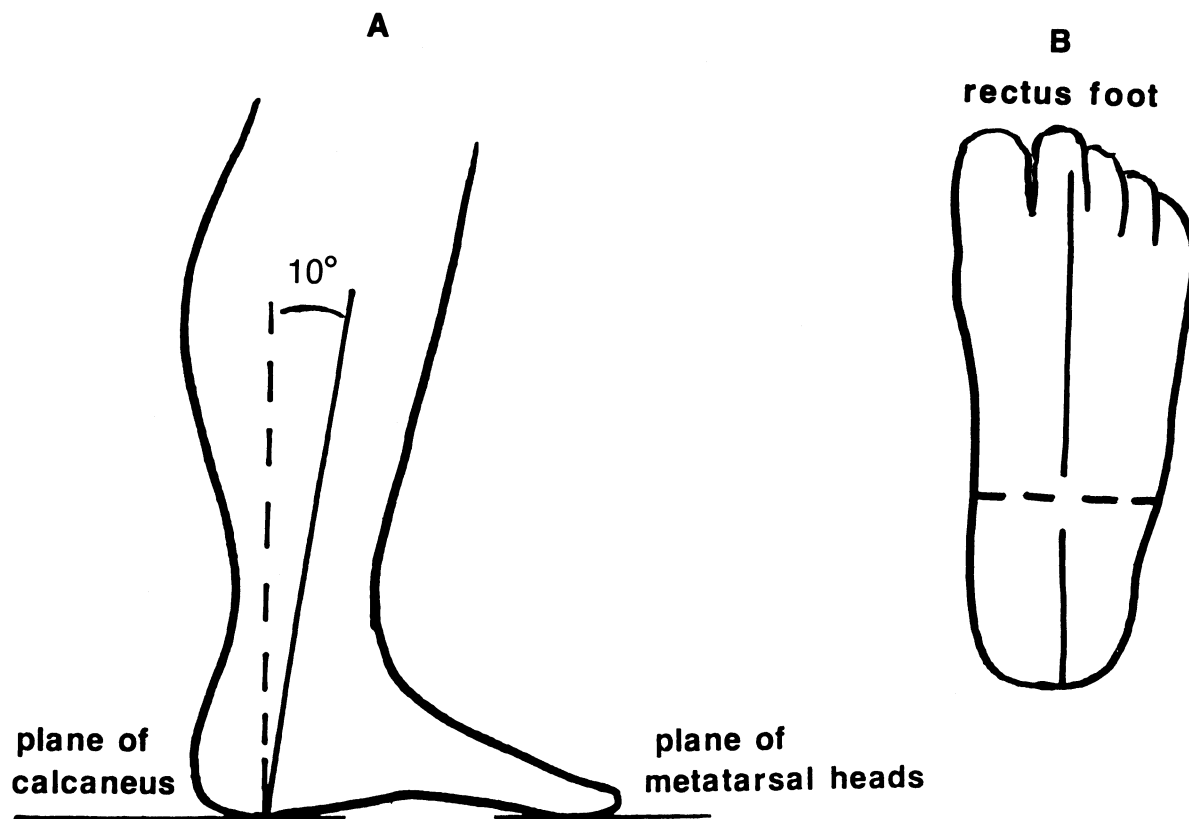


Fig. 5. (A) Closed-chain ankle dorsiflexion with the calcaneus and the metatarsal heads in the same plane; (B) rectus foot alignment in subtalar joint neutral position. (Reprinted by permission of On-Site Biomechanical Education and Training, 1988.)

to complete the ontogenic derotation during childhood.^{2,3,6,7} The clinical implication of this incomplete derotation (when the STJ is in the neutral position) is that the bisection of the calcaneus is inverted, and the medial plantar condyle of the calcaneus is not on the ground (see article by Bernhardt in this issue). Additionally, if the distal third of the tibia approaches the ground with its distal end inclined medially (internally), rear-foot varus will be increased. This abnormal inclination can be produced by a genu varum or a tibial varum. The combination of calcaneal varus and any medial inclination of the tibia produces the total rear-foot varus (Fig. 6).^{2,6}

Forefoot varus is an osseous deformity of the forefoot. The forefoot-to-rear foot alignment in the frontal plane is abnormal. The most probable cause of this deformity is insufficient developmental rotation of the head of the talus.^{2,3,6-8} If the head of the talus fails to rotate completely, the navicular and first cuneiform will be in a cephalad position, which would leave the medial side of the forefoot higher than the lateral side. This orientation of the metatarsal heads is not perpendicular to the rear foot and, therefore, fails to produce a normal (neutral) forefoot-to-rear foot relationship (Fig. 7). Because the medial side of the foot is higher than the lateral side, the forefoot assumes an inverted, or varus, position; hence, the name forefoot varus. A forefoot varus is a very destructive deformity and is encountered frequently in patients with lower extremity dysfunction, despite a relatively low incidence in the general population.

The opposite structural abnormality, *forefoot valgus*, is present when the plane of the metatarsal head is in an everted,

or valgus, position. Two structural types of forefoot valgus deformities exist: 1) All of the metatarsal heads may be everted, or 2) the first metatarsal head may be plantar flexed while the second to fifth metatarsal heads lie in the appropriate plane (Fig. 8).⁷ Excessive ontogenic rotation of the talar head has been proposed as a possible cause of forefoot valgus.^{6,9} Forefoot valgus may be more common than previously reported.⁵

Forefoot equinus is also a forefoot deformity but occurs in the sagittal plane. The plane across the metatarsal heads, although possibly perpendicular to the calcaneal bisection, does not lie in the same plane as the plantar condyles of the calcaneus (Fig. 9).¹⁰ The metatarsals lie below the calcaneus, and, therefore, the forefoot structure is plantar flexed when compared with the rear foot.

MANIFESTATIONS OF ABNORMAL FOOT MECHANICS

Determination that a structural foot deformity exists is not a sufficient basis for providing treatment. Treatment is dictated by the STJ compensations that may occur secondary to the deformities. The STJ compensation, more than the deformity, produces the deleterious effects on the musculoskeletal system. Abnormal foot mechanics are manifested in three general ways during dynamic function (G. W. Gray, personal communication, January 1985).¹ The amount, speed, or timing of STJ motion may be abnormal.

Motion is abnormal if the excursion through which the

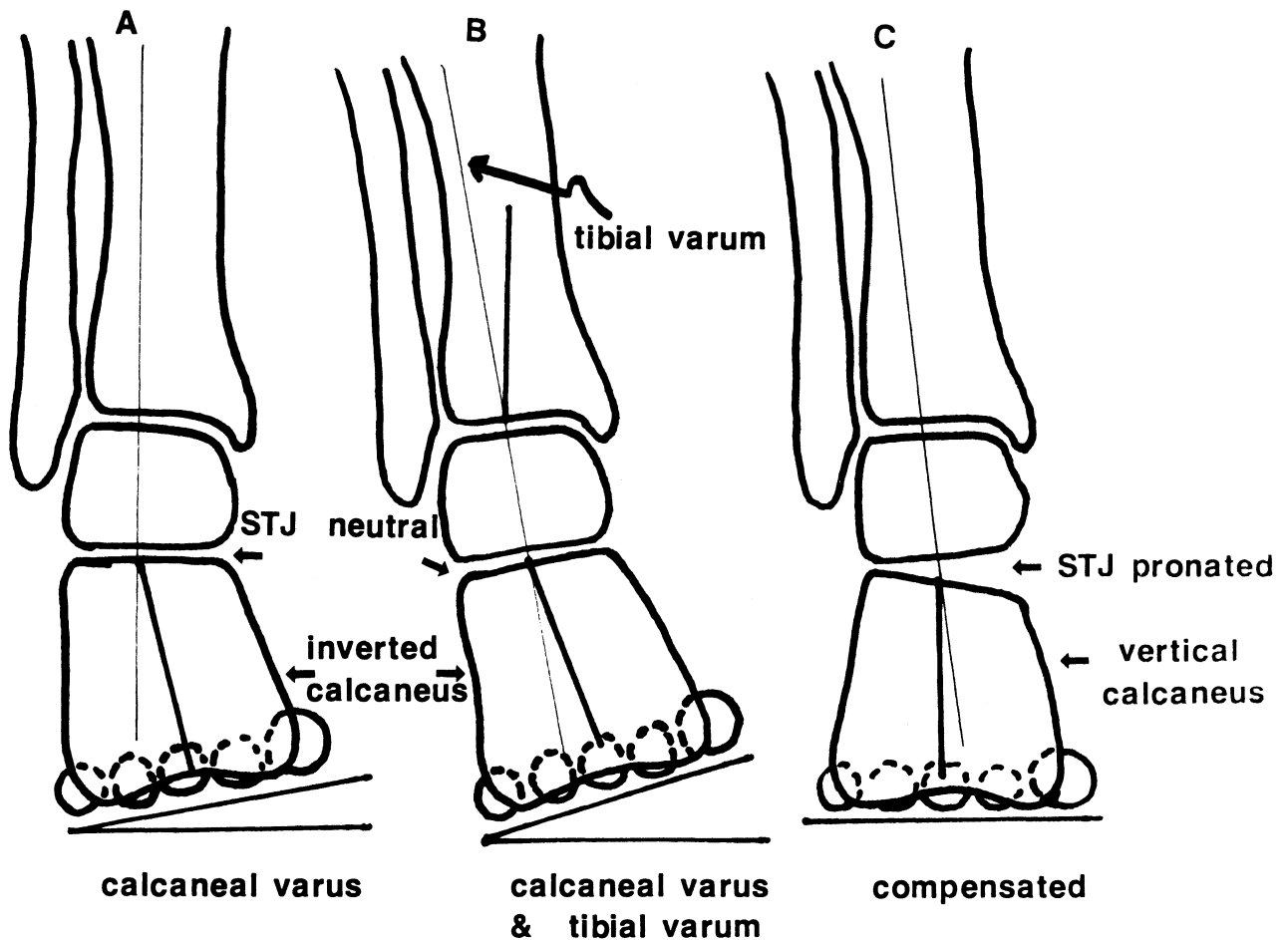


Fig. 6. Rear-foot varus: (A) calcaneal varus; (B) combined calcaneal varus and tibial varum; (C) weight-bearing position after subtalar joint (STJ) compensation. (Reprinted by permission of On-Site Biomechanical Education and Training, 1988.)

joint moves is larger or smaller than normal excursion. Too much motion of a joint can create a number of challenges to the musculoskeletal tissues. The muscle-tendon units may become overstressed while trying to decelerate or control the excessive motion. Excessive motion may reach the limits of joint excursion and stress the noncontractile tissue of the joint (capsule and ligaments). Too little motion of the STJ, however, tends to reduce dissipation of ground-reaction forces and may increase the forces applied to the articular surfaces of the joint.

The second manifestation—speed—is generally a problem of motion occurring too quickly. Increased speed of motion may stress the muscle-tendon unit. Excessive stress in the tendon is particularly likely to occur during eccentric contractions as the muscles attempt to decelerate joint motion. The maximum tension in the tendon is greater during eccentric contractions because of the series elastic component. In addition, under controlled conditions, the tension increases as the speed of motion increases during eccentric contractions.¹¹

The third manifestation of abnormal foot mechanics is the disruption of the temporal sequence of joint motion. When the STJ pronates or supinates at the wrong time, normal foot functions may be compromised. In addition, the poorly timed motion may disrupt the synchronous action of the joints of the entire lower quarter. As a result, excessive stress may be placed on the forefoot during propulsion or on the supporting structures of the proximal joints.

Subtalar Joint Compensation for Structural Deformities

Structural foot deformities would make human locomotion difficult, if not impossible, if the foot were a rigid structure. The foot is able to compensate for these structural deformities through the motion of the STJ and the midtarsal joint (MTJ). The functional problem created by structural deformities is that the foot does not rest securely on the ground surface. For the foot to acquire stable ground contact, the STJ usually will attempt to compensate for these deformities.^{1,12} The motion of the STJ occurs primarily in the frontal and transverse planes, allowing the STJ to effectively compensate for structural deformities in the frontal plane (ie, varus and valgus). Initially, STJ compensations would appear to be beneficial because they allow for relatively normal locomotion, particularly when the foot must adjust for variability in the ground contour. When the compensation is a constant occurrence secondary to structural foot deformities, however, it becomes abnormal.¹ Abnormal STJ compensation may eventually create enough stress on tissues that symptoms are generated. Symptoms may occur anywhere in the lower quarter, but the deleterious effects resulting from specific foot deformities can be anticipated if the STJ compensations are understood.

Rear-foot Varus

At heel-strike, the STJ is slightly supinated, and the lower limb is adducted. As a result, the calcaneus is inverted, and

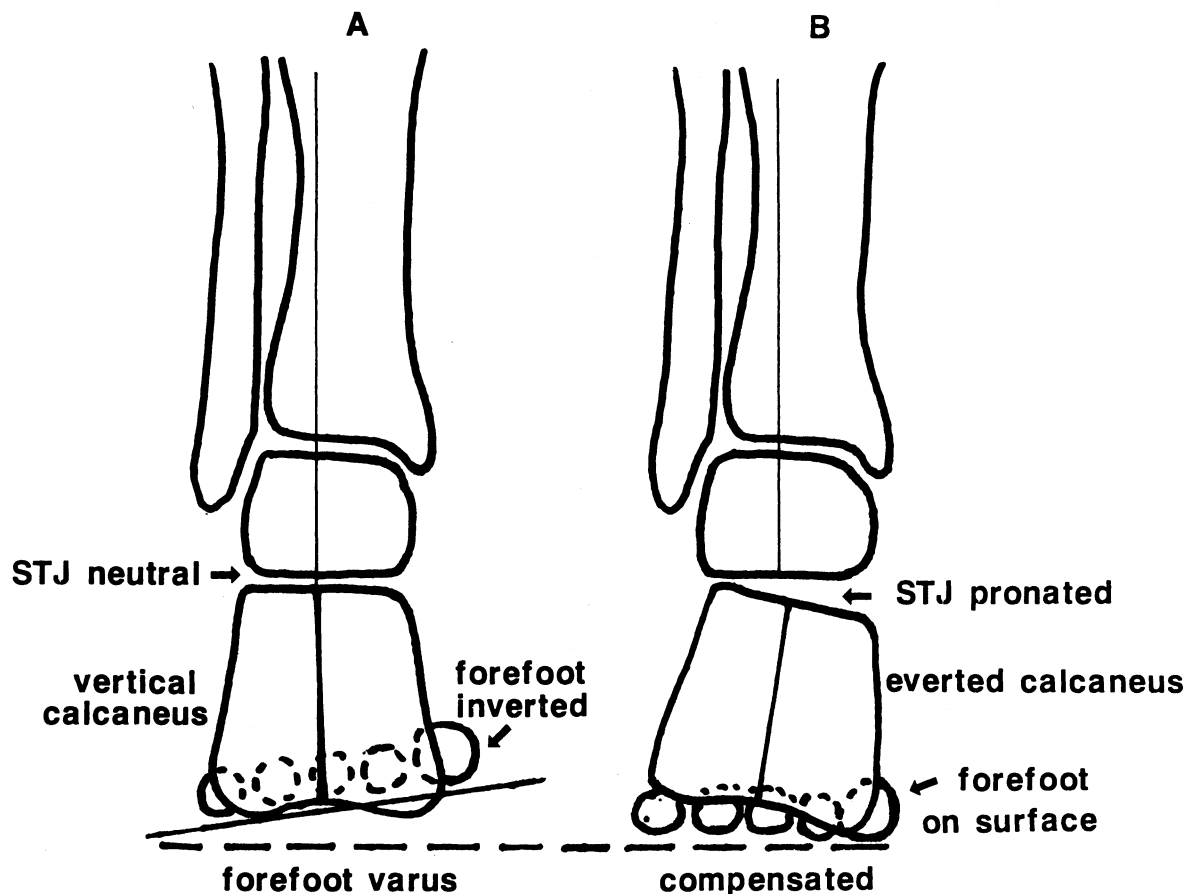


Fig. 7. Forefoot varus: (A) forefoot inverted (varus) relative to a normal calcaneus; (B) weight-bearing position after subtalar joint (STJ) compensation. (Reprinted by permission of On-Site Biomechanical Education and Training, 1988.)

ground contact occurs on the lateral aspect. The practical significance of a rear-foot varus is that at heel-strike the calcaneus is inverted more than normal, and the medial condyle of the calcaneus is farther from the ground (Figs. 6A, 6B). To bring the medial side of the foot to the ground, the calcaneus must evert. Eversion of the calcaneus is produced by STJ pronation, because eversion is a single-plane component of pronation. The STJ goes through an abnormal amount of pronation in compensating for the rear-foot varus (Fig. 6C).^{2,13} Not only is the amount of motion too much, but motion probably will occur too rapidly. An abnormal temporal sequencing, the third manifestation, is not relevant to a rear-foot varus because the STJ motion follows the normal pattern of pronation during the contact phase and supination during mid-stance and propulsion.

The deleterious effects experienced by the forefoot as a result of abnormal STJ pronation secondary to a rear-foot varus are frequently insignificant. Distal foot symptoms may result if the degree of rear-foot varus is large or if the patient is involved in work or sports activities that increase the tissue stresses. When the rear-foot varus is large, the MTJ and the forefoot may be excessively mobile when the heel rises from the ground during propulsion. In the normal foot, the STJ passes from a pronated to a supinated position just before heel rise. Movement of the STJ into a supinated position reduces the mobility of the MTJ ("locks" the MTJ).¹⁴ When the rear-foot varus is large, although the STJ is moving toward a supinated position, the foot may not become rigid until

after the heel rises. Whenever propulsion occurs before the foot has been locked by a supinated position of the STJ, forefoot symptoms and tissue trauma are likely to occur, because the bones are not properly stabilized. Tissue disorders include plantar fasciitis (see article by Riddle and Freeman in this issue), metatarsalgia or stress fractures of the second ray, and hallux abducto valgus. All of these tissue disorders are more likely to occur with a forefoot varus; therefore, the biomechanical causes will be discussed with that structural deformity.

Callus formation on the bottom of the foot can be considered a distal effect of abnormal foot mechanics. Calluses are the body's way of protecting the skin from excessive shearing forces between the underlying bones and the insole of the shoe. An ulcer will form instead of a callus with certain diseases that compromise the body's protective mechanism (see article by Sims et al in this issue). In many instances, calluses form in clearly identifiable patterns that indicate how the foot is functioning.^{1,15} When specific foot deformities produce the anticipated STJ compensation, characteristic callus patterns will form.

In response to a rear-foot varus, a callus will form under the second metatarsal head and to a lesser degree under the third and fourth metatarsal heads.¹⁵ The biomechanical reason for calluses in this location is the fact that the metatarsal heads move across the skin because the foot is not fully stabilized when propulsion begins. The callus does not occur under the first metatarsal head because its stability depends

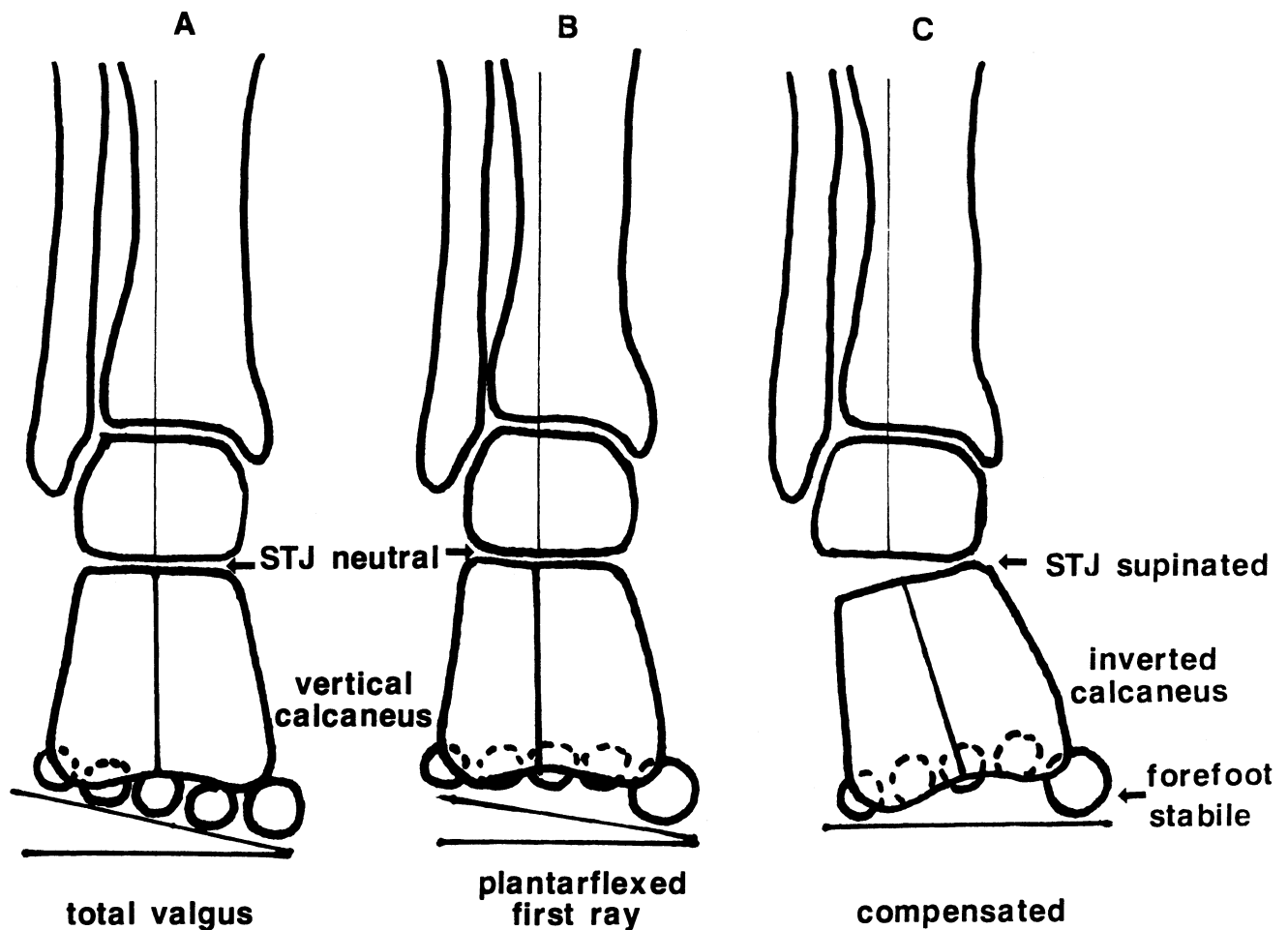


Fig. 8. Forefoot valgus: (A) all metatarsal heads everted (valgus); (B) valgus secondary to a plantar-flexed first ray; (C) weight-bearing position after subtalar joint (STJ) compensation for a rigid forefoot valgus. (Reprinted by permission of On-Site Biomechanical Education and Training, 1988.)

on a contraction of the peroneus longus muscle. A pronated foot decreases the mechanical advantage of the peroneus longus muscle. The first metatarsal is unstable (hypermobile), and the second metatarsal suffers the consequences. In addition, a callus may form on the medial side of the distal phalanx of the hallux. A callus in this location is called a *pinch callus*, because it forms when the medial side of the hallux rubs against the inside of the shoe. A pinch callus frequently occurs when an individual propels off of an abducted forefoot. The abducted position of the forefoot is created when the STJ is still pronated as the heel leaves the ground. A pinch callus forms when the calcaneal varus is large but is seen more commonly with a forefoot varus or with lateral rotation deformities of the leg.

The proximal effects of STJ compensation for a rear-foot varus are substantial. The extra pronation that is occurring too quickly during the contact phase of gait puts a tremendous stress on the muscles that decelerate STJ pronation, primarily the tibialis posterior muscle. The tensile forces in the tendon during the eccentric contraction are increased by the speed of motion.^{11,16} Symptoms of overuse may occur in the tibialis posterior muscle 1) at the distal attachment of the tendon to the navicular and first cuneiform, 2) in the tendon sheath as the tendon glides around the medial malleolus, or 3) at the proximal attachment of the muscle to the bones of the lower

leg. This last site is the most frequent source of symptoms. The specific tissue problem has been described as *periostitis*, or tearing away of the muscle fibers where they attach to the upper half of the tibia.

In addition to the extreme stress placed upon the tibialis posterior muscle, abnormal STJ pronation may produce excessive medial rotation of the lower leg. Because of the obligatory relationship between STJ motion and lower leg rotation, whenever the STJ pronates during weight-bearing, the lower leg must medially rotate.^{1,14,17} The extra rotation must be absorbed in the knee, hip, or sacroiliac joint (SIJ) or between vertebral segments, and in some individuals may become symptomatic. In addition, the frontal-plane component of abnormal STJ pronation increases the valgus stress on the knee. Occasionally, this valgus stress exceeds the threshold of the medial stabilizing structures of the knee, and symptoms of a mild strain (Grade I) of the medial collateral ligament will arise.

Although abnormal STJ pronation is the most frequent compensation for a rear-foot varus, alternative compensations may occur. Partial compensation has occurred if the STJ pronates abnormally but does not have enough available pronation range of motion to bring the medial condyle of the calcaneus to the ground. The foot must find another way to bring the medial side of the foot to the ground.¹⁸ The rear

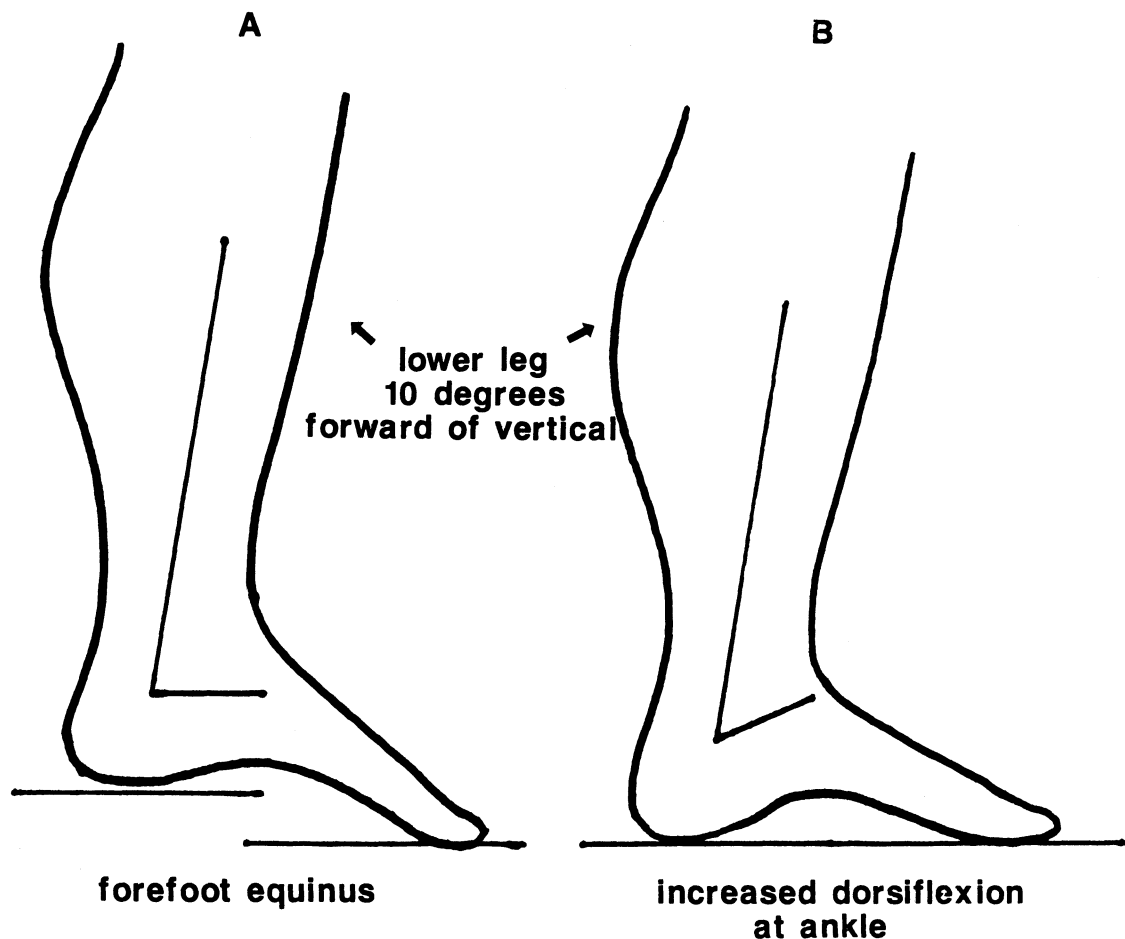


Fig. 9. Forefoot equinus: (A) forefoot plantar flexed relative to the rear foot; (B) increased dorsiflexion at the ankle in weight-bearing position. (Reprinted by permission of On-Site Biomechanical Education and Training, 1988.)

foot will usually achieve full-surface contact through a wedging of the heel pad from weight-bearing forces. Medial forefoot contact can be achieved by MTJ pronation or plantar flexion of the first ray (partial compensations). This latter compensation may alter the callus pattern slightly by creating a small callus under the first metatarsal head.

There are instances when the STJ fails to compensate by pronating. This failure results in an uncompensated rear-foot varus with callus formation, which is greatest under the fifth metatarsal head.¹⁵ The symptoms resulting from an uncompensated varus would be different. Because the STJ fails to pronate, the foot does not facilitate the normal shock-absorbing mechanism at the knee. An uncompensated varus is more common with a forefoot varus.

Forefoot Varus

The foot with a structural forefoot varus has a normal calcaneus that is parallel to the ground when the STJ is in the neutral position (Fig. 7A). When the lateral border of the heel strikes the ground, therefore, a normal amount of STJ pronation occurs. When the medial condyle reaches the ground, the STJ should reverse its direction and begin supinating. With a forefoot varus, however, the medial side of the forefoot is not touching the ground. To assist the medial side of the forefoot in reaching the ground, the STJ may pronate as the mid-stance phase begins (Fig. 7B).^{7,12,13} This pronation is

abnormal because it is excessive and because it is occurring at the wrong time. A forefoot varus, therefore, will manifest itself in an excessive amount of pronation combined with abnormal temporal sequencing. The STJ compensates for a forefoot varus by pronating abnormally like a rear-foot varus, but unlike a rear-foot varus, the pronation occurs during the mid-stance and propulsion phases.

As a result of this compensatory pronation of the STJ during the mid-stance phase, the MTJ becomes maximally mobile at the time when a normal foot would be reaching a supinated position just before propulsion.^{1,14,19} The MTJ remains unlocked throughout propulsion, creating extreme stresses on the tissue in the forefoot. The plantar fascia, which tightens via the "windlass" effect when the heel rises,^{14,20} experiences an inordinate amount of stress in attempting to support the arch of the foot (see article by Riddle and Freeman in this issue). In the normal foot, the mobility in the MTJ is reduced and the mechanical advantage of the muscles is enhanced when the STJ is in a supinated position.^{1,21} When propulsion takes place off of a pronated foot, these normal stabilizing mechanisms are lost. The plantar fascia must attempt to support the arch alone and at some point may become symptomatic.

The first ray is unstable (hypermobile) with a compensated forefoot varus.¹ The ligamentous and muscular stabilizers are ineffective because of the pronated position in the STJ. The second metatarsal head will experience excessive loading be-

cause the first ray-hallux complex cannot effectively contribute to propulsion. The resultant metatarsalgia or stress fracture of the second metatarsal is not difficult to anticipate.

Another distal effect commonly encountered with a forefoot varus is the development of a hallux abductovalgus deformity (HAV bunion).^{1,12} The biomechanical basis of this deformity is multifactorial, but propulsion off of a forefoot that is abducted as a result of abnormal pronation is frequently the underlying catalyst.¹ Clinical observation of gait in patients with a HAV deformity readily reveals the abnormal forces on the hallux during the propulsion phase. The ground-reaction forces pass along the side of the hallux and combine with the hypermobility of the first ray to produce a long-term structural change in the first metatarsophalangeal (MTP) joint. These three clinical problems in the distal foot, and countless other problems, result from propulsion off of a hypermobile foot. As with rear-foot varus, the callus formation will be primarily under the second metatarsal head. The callus formation is often extreme, and the pinch callus is almost always present because the foot remains abnormally pronated throughout the propulsion phase.^{12,15}

The proximal effects of a forefoot varus frequently produce tissue symptoms. The severity of these proximal stresses is due to the fact that the STJ pronation is occurring at the wrong time. Pronation occurs when the STJ should be supinating and the lower leg should be rotating laterally. This lateral rotation of the lower leg is essential for the synchronous action of the knee, hip, and pelvis. If the lateral rotation that accompanies STJ supination is not present, the synchrony is disrupted, and the lower extremity must find some way to adjust. During the mid-stance phase when the STJ is pronating abnormally, the knee is moving toward terminal extension. Terminal extension requires the tibia to laterally rotate on the femur. With a forefoot varus, the abnormal pronation during mid-stance denies the knee of the necessary medial rotation and creates a biomechanical dilemma for the knee.²² The knee cannot extend without the rotation; if it attempts to do so, the supporting structures of the knee may be traumatized.

If the knee joint avoids this dilemma by having the femur rotate medially with the tibia, the problem is transferred to a more proximal structure. If the poorly timed rotation is absorbed at the hip joint, a piriformis muscle syndrome or SIJ dysfunction could result. The piriformis muscle laterally rotates the femur. During closed-chain dynamic function, the piriformis muscle decelerates the medial rotation of the femur on the pelvis. The piriformis muscle affects the SIJ by virtue of its attachment to the anterior aspect of the sacrum. During the mid-stance phase, the pelvis reverses direction to move forward with the swinging leg. If the femur medially rotates secondary to the forefoot varus, the bony attachments of the piriformis muscle will be pulled in opposite directions, increasing stress to both contractile and noncontractile tissues. Stress would be transferred to the lumbosacral spine if the pelvis were to compensate by moving with the femur. Symptoms, therefore, can develop anywhere along the lower extremity chain, especially where predisposing factors make tissues susceptible to failure.

As was mentioned with rear-foot varus, the STJ may fail to compensate for a structural abnormality.¹⁸ In the case of a forefoot varus, the STJ may have only enough ROM, once the calcaneus is on the ground, to partially compensate for the forefoot varus. Residual compensation for the forefoot varus usually occurs at the MTJ (pronation) or at the first ray

(plantar flexion). The STJ may not compensate for the forefoot varus at all. If the STJ does not pronate, the mobility of the MTJ is restricted, and the patient would exhibit an uncompensated forefoot varus. Weight is borne primarily on the lateral border of the foot, producing the characteristic callus under the fifth metatarsal head.¹⁵ The symptoms of an uncompensated varus may be focused on the lateral border of the foot. Proximal synchrony is not disrupted during the mid-stance phase when the forefoot varus is uncompensated. Instead, the patient's proximal symptoms may be similar to symptoms produced from a failure to attenuate shock because the STJ is not pronating enough.

Forefoot Valgus

A forefoot valgus, as described earlier, is a structural deformity that occurs when the forefoot is everted relative to the rear foot, bringing the medial side of the foot below the lateral side (Figs. 8A, 8B). To understand the pathomechanical manifestations of this foot type, a differentiation must be made between a flexible forefoot valgus and a rigid forefoot valgus.⁷ A *flexible valgus* usually develops secondary to an uncompensated or partially compensated rear-foot varus. A flexible forefoot valgus, therefore, will be discussed in the section on combined foot types. The remainder of this section will focus on a forefoot valgus that is rigid and that cannot be eliminated when the ground-reaction force pushes against the foot during standing.⁴

If no STJ compensation occurs in response to a forefoot valgus, all of the body weight would be borne on the medial side of the forefoot. The foot would be relatively unstable. Achieving stability by bringing the lateral side of the foot to the ground is accomplished by STJ supination.^{6,8,13} As the STJ begins to move from a supinated to a pronated position at heel-strike, the medial side of the forefoot strikes the ground, forcing the STJ back into a supinated position (Fig. 8C). This supination prevents the normal STJ pronation during the contact phase. The manifestation of a rigid forefoot valgus, therefore, is a foot that exhibits too little pronation and then returns to a supinated position much sooner than would a normal foot.⁴

One of the distal effects of the abnormally supinated foot is that the MTJ never attains the mobility required for the foot to adapt to the ground. The rigid foot has difficulty moving across uneven terrain. A foot with a forefoot valgus also is very susceptible to lateral inversion (supination) ankle sprains. The STJ is supinated when this foot is on the ground in its compensated position, creating a situation where the STJ is much closer to the end of the ROM than it would be in a normal foot (Fig. 8C). The proximity to the end of the ROM reduces the amount of time that the muscles have to contract to prevent a lateral ankle sprain. Additionally, because the MTJ and the rest of the foot are hypomobile, the effect of any object or undulation under the forefoot will immediately be transferred to the STJ, increasing the likelihood of ligamentous injury.

Other distal effects involve the first ray and hallux. If the forefoot valgus results from a rigid plantar-flexed position of the first ray, then the normal motion of the first MTP joint during locomotion may be compromised (Fig. 8B). As the heel rises from the ground during propulsion, the MTP joint must have 65 to 70 degrees of dorsiflexion.¹ For this amount of dorsiflexion to occur, the first ray must plantar flex more than the second ray during the propulsive sequence. If the

first ray is plantar flexed and rigid, it frequently is unable to plantar flex further to supply the first MTP joint with the necessary dorsiflexion. Failure to plantar flex alters the arthrokinematics of the first MTP joint and in some cases will lead to the degenerative changes that produce hallux limitus-rigidus.^{1,13} Callus formation in the rigid forefoot valgus occurs under the first and fifth metatarsal heads.¹⁵ The callus under the first metatarsal head will be accentuated when the forefoot valgus is the result of a plantar-flexed first ray.

The proximal effects of a compensated forefoot valgus lie primarily in the fact that the shock-absorbing ability of the knee is compromised.^{1,2} The STJ fails to pronate, thereby denying the knee the medial rotation of the lower leg required for flexion. Knee flexion during the contact phase is delayed for a short time. This delay allows increased forces to travel up the lower extremity. The increased forces may contribute to the development of central patellofemoral pain or sacral and low back dysfunction. The supinated position of the STJ also increases the varus stress on the knee and may be a factor in the development of problems around the lateral aspect of the knee.

The ways for the body to compensate for a rigid forefoot valgus, other than abnormal STJ supination, are limited. These alternative mechanisms are usually activated during propulsion. The normal shift of the center of mass from one leg to the other becomes difficult because of the failure of the STJ to pronate. The normal lateral-to-medial weight transfer across the forefoot during propulsion may be accomplished by lifting the lateral border of the foot off the ground.¹

Forefoot Equinus

Forefoot equinus is a plantar-flexed position of the forefoot when compared with the rear foot (Fig. 9A).¹² The functional effect of this deformity is that the ankle joint must move through a greater excursion of dorsiflexion to allow the body to move forward over the foot during the mid-stance phase (Fig. 9B). If enough ankle joint motion occurs, no additional compensation is required. If ankle joint motion is insufficient, compensation will occur elsewhere in the lower extremity.

The STJ is unable to compensate directly for a forefoot equinus because it has very little motion in the sagittal plane (dorsiflexion).¹⁰ Other than the ankle joint, the most effective source of dorsiflexion is the MTJ. If the MTJ is to provide the dorsiflexion to compensate for the forefoot equinus, it must be mobile. A mobile MTJ is created when the STJ is in a pronated position.⁶ The time when maximum dorsiflexion is needed at heel rise, however, is also the time when the STJ should be in a supinated position for propulsion. The abnormal STJ pronation in the mid-stance phase, as a compensation for forefoot equinus, may produce clinical symptoms similar to the distal effects encountered with a compensated forefoot varus.¹⁰

In many instances, a forefoot equinus occurs in a foot that also has a rigid forefoot valgus. The compensatory mechanism described above is not possible because the STJ cannot pronate. In this case, the compensation and the associated clinical symptoms are more proximal in the leg. If there is not enough motion in the sagittal plane (dorsiflexion) at the ankle, then motion in the sagittal plane may be achieved at the knee joint. As the body progresses forward over the foot and the tibia is unable to move forward, a hyperextension force is created at the knee joint.

Additional stress may occur at the ankle. The tibia, as it

tries to move forward against the resistance of the soft tissues, will produce a change in the normal joint arthrokinematics. The rolling component of the articular motion decreases, and the neck of the talus may contact the anterior lip of the tibia. Repetitive contact on this nonarticular surface may produce a talar exostosis.^{1,13,23} As indicated by these examples, the clinician should realize that compensatory mechanisms often shift the tissue stress from the site of the deformity or the site of the compensation.

Combined Rear-foot and Forefoot Deformities

The common structural foot deformities frequently occur together. A rear-foot varus can occur with either a forefoot varus or forefoot valgus. The manifestations of the combined foot deformities may be slightly different from the individual structural abnormalities. In a foot that exhibits a rear-foot and a forefoot varus, the abnormal compensatory pronation at the STJ is accentuated. The STJ pronation is abnormal throughout the contact, mid-stance, and propulsion phases of the gait cycle. The STJ pronates too much and too rapidly during contact because of the rear-foot varus and pronates too much and at the wrong time because of the forefoot varus. The patient may demonstrate both distal and proximal effects. The amount of obligatory medial rotation of the leg that accompanies the abnormal STJ pronation is extreme. Proximal dysfunction is more likely to occur with both deformities, therefore, than with either deformity alone.

A rear-foot varus may also be combined with a flexible forefoot valgus. The forefoot valgus may have developed secondary to a partially compensated rear-foot varus. Based on the description of STJ compensation with a rigid forefoot valgus, it would seem that STJ pronation would be limited. Clinically, however, this foot type demonstrates a significant amount of pronation during stance.^{4,13} As the STJ begins to pronate, MTJ mobility increases, and the forefoot valgus becomes flexible. If STJ pronation is not sufficient to bring the medial side of the forefoot to the ground, pronation will occur at the MTJ. The foot definitely is abnormally pronated, but the abnormal pronation occurs at the MTJ as well as at the STJ. Although slight evidence of callus formation may exist under the first metatarsal head, the foot is clearly an abnormal pronator and will exhibit a pronounced callus under the second metatarsal head.

The third combination of foot deformities occurs when a rigid forefoot valgus is present with a rear-foot varus. This combination is not uncommon and creates extreme bone stress in the middle of the foot. As the heel strikes the ground, the STJ begins to pronate in response to the rear-foot varus. When the forefoot reaches the ground, the forefoot valgus begins to take effect. The normal compensation for a forefoot valgus is STJ supination to get the lateral side of the foot to the ground. The motion of the rear foot and forefoot in opposite directions creates a biomechanical dilemma for the foot that is not solved easily. This foot is called a *torque foot* because of the torsional stresses that are inflicted on the tarsal bones. Degenerative joint changes and tarsal stress fractures are potential problems, in addition to the lateral ankle sprains and proximal problems described with a forefoot valgus.

DISCUSSION

Clinical observations and, to a limited degree, research findings indicate that the STJ is the most frequent site of

compensation for structural foot deformities. The STJ compensation provides the motion needed to minimize the disruption of human locomotion created by the foot deformities. Many of the foot deformities are single-plane deformities, but the compensatory motion at the STJ or MTJ occurs in more than one plane. In addition to excessive motion, motion occurring too rapidly, or motion occurring at the wrong time, therefore, unnecessary motion occurs in the other cardinal planes.¹

This article concentrated on abnormal compensations of the STJ. Brief mention was made of partial and alternative compensations at the MTJ. The MTJ is responsible for making adjustments between the forefoot and rear foot consistent with the foot's function as a mobile adapter. Compensations for foot deformities that occur at the MTJ are probably better tolerated than those at the STJ but still hold the potential for tissue breakdown. Variations in the structural alignment of the MTJ in different individuals will alter the specific compensations. These MTJ compensations have not been described completely and are beyond the scope of this article.

The compensation of the STJ (or MTJ) solves the immediate problem but creates stress on tissues elsewhere in the lower quarter. This biomechanical transfer of stress does not always produce symptomatic tissue dysfunction. The tissue may respond by becoming stronger according to Wolff's law. When the tissue stress exceeds the symptomatic threshold, however, therapeutic intervention must include treatments directed at the symptoms, the biomechanical cause of the symptoms, and any predisposing factors that might be contributing to tissue breakdown.

The abnormal stress that results from the structural foot abnormalities does not commonly exceed the symptomatic threshold in young children. The plasticity of the musculoskeletal tissues and the enhanced tissue repair rate combine to reduce the occurrence of symptoms. The plasticity of the musculoskeletal tissues, unfortunately, leaves children susceptible to the development of structural malalignment as a result of abnormal foot mechanics during development. The osseous development of the foot is discussed in the article by Bernhard in this issue, but a brief discussion of the effects of pathomechanics is warranted here.

The criteria that define a normal foot are not present at the time of birth. Both the posterior aspect of the calcaneus and the head of the talus must undergo an ontogenic derotation to achieve normal alignment. Until this derotation is complete at 8 or 9 years of age, most children will have a calcaneal varus and a forefoot varus,³ which will cause them to pronate excessively. Some children exhibit more pronation than can be attributed to the incomplete development of the foot, which may indicate the presence of structural foot deformities. This abnormal pronation often is ignored because of the lack of symptoms and the expected reduction of this pronation during development. The abnormal amount of childhood pronation will affect the alignment of proximal osseous structures. The abnormal pronation, which increases the valgus stress on the adult knee, will create a valgus deformity in the developing knee. In addition, the obligatory medial rotation that accompanies STJ pronation may inhibit the normal ontogenic reduction of femoral anteversion. The components of "miserable malalignment syndrome"²⁴ encountered in clinical practice are probably the product of abnormal biomechanical forces during childhood rather than of a chance association.

Relief from symptomatic tissue stress in adults or facilitation of normal osseous alignment in children requires a reduction or elimination of the abnormal STJ compensation. The STJ compensations are beneficial mechanisms responding to structural foot deformities. Attempts to reduce the STJ compensations, therefore, must be directed at the structural deformities through the use of foot orthoses (see article by Lockard in this issue).

SUMMARY

The primary structural foot deformities and most common STJ compensations encountered in clinical practice have been described. Theoretical mechanisms for increased tissue stress and symptoms throughout the lower extremity have been presented. Possible implications on osseous development and a rationale for the use of biomechanical orthoses were discussed briefly. The specific tissue dysfunctions described in this article, although commonly encountered in clinical practice, are but a small portion of the problems that arise from abnormal foot biomechanics.

REFERENCES

1. Root ML, Orien WP, Weed JH: Normal and Abnormal Function of the Foot. Los Angeles, CA, Clinical Biomechanics Corp, 1977
2. McPoil TG Jr, Brocato RS: The foot and ankle: Biomechanical evaluation and treatment. In Gould JA, Davies GJ (eds): Orthopaedic and Sports Physical Therapy. St. Louis, MO, C V Mosby Co, 1985, pp 313-341
3. Straus WL: Growth of the human foot and its evolutionary significance. Contrib Embryol Carnegie Institute 19:93, 1927
4. Langer S: Understanding the plantar-flexed first ray. The Langer Group Newsletter 9(2):4:5,10, 1981
5. McPoil TG Jr, Knecht HG, Schuit D: A survey of foot types in normal females between the ages of 18 and 30 years. Journal of Orthopaedic and Sports Physical Therapy 9:406-409, 1988
6. Sgarlato TE: A Compendium of Podiatric Biomechanics. San Francisco, CA, College of Podiatric Medicine, 1977
7. Hunt GC, Brocato RS: Gait and foot pathomechanics. In Hunt GC (ed): Physical Therapy of the Foot and Ankle. New York, NY, Churchill Livingstone Inc, 1988, pp 39-57
8. Subotnick SI: Biomechanics of the subtalar and midtarsal joints. J Am Podiatr Assoc 65:756-764, 1975
9. Sarrafian SK: Anatomy of the Foot and Ankle: Descriptive, Topographic, Functional. Philadelphia, PA, J B Lippincott Co, 1983
10. Bouche RT, Kuwada GT: Equinus deformity in the athlete. The Physician and Sportsmedicine 12(1):81-91, 1984
11. Stanish WD, Curwin S: Tendinitis: Its Etiology and Treatment. Lexington, MA, D C Heath & Co, 1984
12. Hlavac HF: Compensated forefoot varus. J Am Podiatr Assoc 60:229-233, 1970
13. Weissman SD: Radiology of the Foot. Baltimore, MD, Williams & Wilkins, 1983
14. Inman VT, Ralston HJ, Todd F: Human Walking. Baltimore, MD, Williams & Wilkins, 1981
15. Gray GW: When the Feet Hit the Ground Everything Changes: Program Outline and Prepared Notes—A Basic Manual. Toledo, OH, American Physical Rehabilitation Network, 1984
16. Winter DA: Biomechanics of Human Movement. New York, NY, John Wiley & Sons Inc, 1979
17. Wright DG, Desai SM, Henderson WH: Action of the subtalar and ankle-joint complex during the stance phase of walking. J Bone Joint Surg [Am] 46:361-382, 1964
18. Making the diagnosis: Uncompensation vs partial compensation vs full compensation. Langer Biomechanics Newsletter 6(1), 1978
19. Manter JT: Movement of the subtalar and transverse tarsal joints. Anat Rec 80:397-410, 1941
20. Hicks JH: The mechanics of the foot: 2. The plantar aponeurosis and arch. J Anat 88:25-30, 1954
21. Close JR, Inman VT, Poor PM, et al: The function of the subtalar joint. Clin Orthop 50:159-179, 1967
22. Tiberio D: The effect of excessive subtalar joint pronation on patellofemoral mechanics: A theoretical model. Journal of Orthopaedic and Sports Physical Therapy 9:160-165, 1987
23. Sammarco GJ, Burstein AH, Frankel VH: Biomechanics of the ankle: A kinematic study. Orthop Clin North Am 4:75-96, 1973
24. James SJ: Chondromalacia of the patella in the adolescent. In Kennedy JC (ed): The Injured Adolescent Knee. Baltimore, MD, Williams & Wilkins, 1979, pp 205-251

Physical Therapy

Journal of the American Physical Therapy Association



Pathomechanics of Structural Foot Deformities

David Tiberio

PHYS THER. 1988; 68:1840-1849.

Cited by

This article has been cited by 7 HighWire-hosted articles:

<http://ptjournal.apta.org/content/68/12/1840#otherarticles>

Subscription Information

<http://ptjournal.apta.org/subscriptions/>

Permissions and Reprints

<http://ptjournal.apta.org/site/misc/terms.xhtml>

Information for Authors

<http://ptjournal.apta.org/site/misc/ifora.xhtml>
